

## PROSTHETIC REHABILITATION OF FOUR ANTERIOR TEETH ASSOCIATED WITH THE USE OF A NANOBIMATERIAL IN GUIDED BONE REGENERATION: CASE REPORT

REABILITAÇÃO PROTÉTICA DE 4 ELEMENTOS ANTERIORES ASSOCIADO AO USO DE NANOBIMATERIAL EM REGENERAÇÃO ÓSSEA GUIADA; RELATO DE CASO

REHABILITACIÓN PROTÉSICA DE 4 DIENTES ANTERIORES ASOCIADA CON EL USO DE NANOBIMATERIAL EN REGENERACIÓN ÓSEA GUIADA: REPORTE DE CASO

João Carlos Amorim<sup>1</sup>, Lucio Frigo<sup>2</sup>, Saulo Henrique Salviano<sup>3</sup>, Santiago Estrems Dias<sup>4</sup>, Gustavo Helder Vinholi<sup>5</sup>, Igor da Silva Brum<sup>6</sup>, Jorge José de Carvalho<sup>7</sup>

DOI: 10.54899/dcs.v23i87.4552

Recibido: 09/01/2026 | Aceptado: 30/01/2026 | Publicación en línea: 11/02/2026.

### ABSTRACT

The loss of dental elements due to periodontal disease or carious lesions affects a large portion of the population, causing significant damage to patients' oral health. In this context, the availability of nanobiomaterials and implants with high osseointegration rates allows greater predictability of treatments. The present clinical case reports the loss of teeth #11, #12, #21, and #22 due to periodontal disease and prosthetic maladaptation. The proposed treatment involved the removal of the four teeth and placement of two Systhex® implants (Curitiba, Brazil) (Avant model, 3.5 × 13 mm) in the regions of teeth #12 and #22, associated with the use of the Nanoenxerto Blue Bone® (Curitiba, Brazil) and a Green Membrane® with dimensions of 20 × 25 mm and 1 mm thickness (Curitiba, Brazil) to cover and protect the nanograft. Subsequently, two 2-mm-high mini abutments were installed and an immediate provisional prosthesis was fabricated. After 4 months of osseointegration, a definitive screw-retained porcelain prosthesis was installed. In conclusion, the use of implants with high osseointegration rates associated with nanobiomaterials allows safe rehabilitation of patients with long-lasting and esthetic results.

<sup>1</sup> PhD in Periodontology, Portuguese Catholic University, Viseu, Portugal. E-mail: lopes.jc@hotmail.com  
Orcid: <https://orcid.org/0000-0002-0164-0670>.

<sup>2</sup> PhD in Science - Cell and Tissue Biology, Universidade de São Paulo, São Paulo, Brazil.  
E-mail: luciofrigo@uol.com.br Orcid: <https://orcid.org/0000-0001-9131-1071>

<sup>3</sup> Specialist in Implant Dentistry, Faculdade de Odontologia de Pernambuco, Recife, Pernambuco, Brazil.  
E-mail: saulohis@yahoo.com.br

<sup>4</sup> Specialist in Implant Dentistry, Estrems Servicio Dental Especializada, Valencia, Spain.  
E-mail: santi\_estrems@hotmail.com

<sup>5</sup> PhD in Health Sciences, Universidade Federal de Mato Grosso do Sul, Campo Grande, Mato Grosso do Sul, Brazil.  
E-mail: gvinholi@yahoo.com.br Orcid: <https://orcid.org/0000-0002-6879-1713>

<sup>6</sup> PhD in Experimental Pathophysiology, Universidade do Estado do Rio de Janeiro, Rio de Janeiro, Rio de Janeiro, Brazil. E-mail: igor\_brum1@hotmail.com Orcid: <https://orcid.org/0000-0002-7522-205X>

<sup>7</sup> PhD in Histology, Universidade de São Paulo, São Paulo, Brazil. E-mail: jjcarv@gmail.com

**Keywords:** Dental Implants. Nanobiomaterial. Graft. Osseointegration.

### RESUMO

A perda de elementos dentários devido a doença periodontal ou lesões cáries afeta grande parte da população, causando danos significativos à saúde bucal dos pacientes. Nesse contexto, a disponibilidade de nanobiomateriais e implantes com altas taxas de osseointegração permite maior previsibilidade dos tratamentos. O presente caso clínico relata a perda dos dentes 11, 12, 21 e 22 devido a doença periodontal e má adaptação protética. O tratamento proposto consistiu na extração dos quatro dentes e na colocação de dois implantes Systhex® (Curitiba, Brasil) (modelo Avantt, 3,5 × 13 mm) nas regiões dos dentes 12 e 22, associados ao uso do Nanoenxerto Blue Bone® (Curitiba, Brasil) e de uma membrana Green Membrane® com dimensões de 20 × 25 mm e 1 mm de espessura (Curitiba, Brasil) para cobertura e proteção do nanoenxerto. Em seguida, foram instalados dois mini-abutments de 2 mm de altura e confeccionada uma prótese provisória imediata. Após 4 meses de osseointegração, foi instalada uma prótese definitiva de porcelana parafusada. Em conclusão, o uso de implantes com altas taxas de osseointegração associadas a nanobiomateriais permite a reabilitação segura de pacientes com resultados estéticos e duradouros.

**Palavras-chave:** Implantes Dentários. Nanobiomaterial. Enxerto. Osseointegração.

### RESUMEN

La pérdida de elementos dentales debido a la enfermedad periodontal o lesiones cáries afecta a una gran parte de la población, causando daños significativos a la salud bucal de los pacientes. En este contexto, la disponibilidad de nanobiomateriales e implantes con altas tasas de osteointegración permite una mayor previsibilidad de los tratamientos. El presente caso clínico reporta la pérdida de los dientes n.º 11, n.º 12, n.º 21 y n.º 22 debido a la enfermedad periodontal y la mala adaptación protésica. El tratamiento propuesto consistió en la extracción de los cuatro dientes y la colocación de dos implantes Systhex® (Curitiba, Brasil) (modelo Avantt, 3,5 × 13 mm) en las regiones de los dientes n.º 12 y n.º 22, junto con el uso de Nanoenxerto Blue Bone® (Curitiba, Brasil) y una Green Membrane® de 20 × 25 mm y 1 mm de espesor (Curitiba, Brasil) para cubrir y proteger el nanoinjerto. Posteriormente, se instalaron dos mini pilares de 2 mm de altura y se fabricó una prótesis provisional inmediata. Tras 4 meses de osteointegración, se instaló una prótesis definitiva de porcelana atornillada. En conclusión, el uso de implantes con altas tasas de osteointegración, asociados a nanobiomateriales, permite una rehabilitación segura de los pacientes con resultados estéticos y duraderos.

**Palabras clave:** Implantes Dentales. Nanobiomaterial. Injerto. Osteointegración.



Esta obra está bajo una [Licencia Creative Commons Atribución- NoComercial 4.0 Internacional](https://creativecommons.org/licenses/by-nc/4.0/)

## INTRODUCTION

Osseointegration rates have evolved over time. In the early days of implant dentistry, rehabilitation with dental implants required a minimum waiting period of 8 months before initiating the prosthetic phase (Buzatu *et al.*, 2024). Currently, implants placed in healed sockets can be safely rehabilitated with a minimum period of 45 days (Shah *et al.*, 2023).

This significant reduction in osseointegration time is mainly due to advancements in titanium surface technologies. Previously, materials were used to create rough surfaces with numerous contaminants and irregularities. Today, it is possible to precisely measure spacing and depth generated on each engineered surface (Ou *et al.*, 2022).

The macrogeometry of modern implants also plays a fundamental role in achieving better initial anchorage, providing much greater primary stability compared with earlier smooth-surface implants (Heimes *et al.*, 2023).

In many cases, not only the presence of an advanced implant surface or more aggressive threads determines treatment success. Several other factors must be considered, such as the correct choice of biomaterial, given the wide range of options available on the market. Among these, nanobiomaterials have stood out by demonstrating superior results, as they promote more cellular osseointegration and increased vascularization (Dhaliwal *et al.*, 2021; Jadhav *et al.*, 2026).

Nanobiomaterials enhance the interaction between dental implants and native bone by more efficiently managing the inflammatory cascade and regulating factors such as NF- $\kappa$ B, interleukins, TGF- $\beta$ , and BMPs, among others (Roma *et al.*, 2024; Shaheen *et al.*, 2025).

The aim of this study was to demonstrate the effectiveness of a well-positioned implant associated with the use of a nanobiomaterial in the anterior esthetic region.

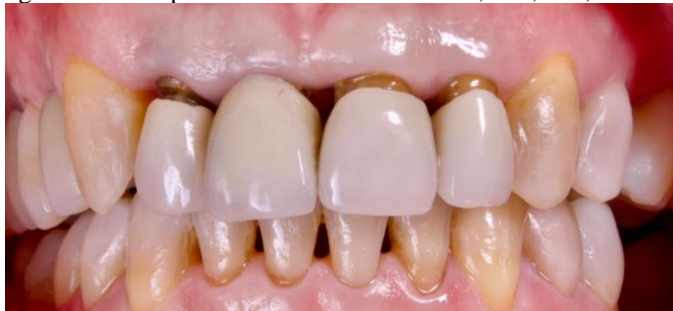## MATERIALS AND METHODS

A 32-year-old male patient, a non-smoker, clinically healthy (without systemic diseases) and without bruxism, sought treatment at the Clínica de Hálito in Pernambuco (PE), Brazil. The patient's main complaint involved dental caries associated with severe periodontal disease affecting the maxillary incisors, resulting in total loss of four coronal structures—#11, #21, #12, and #22—which had recently lost their prosthetic restorations, compromising both function and

esthetics.

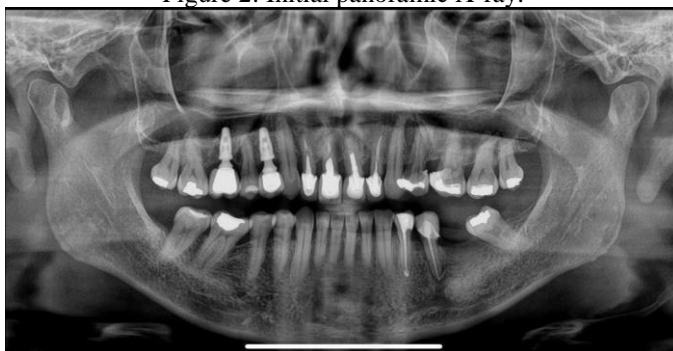Medical history and complementary examinations confirmed normal systemic health. Cone-beam computed tomography (CBCT) confirmed the clinical findings and revealed significant bone loss. The patient provided informed consent for publication of the case details and accompanying images (Figures 1, 2, and 3).

Figure 1: Initial presentation of elements #11, #21, #12, and #22.



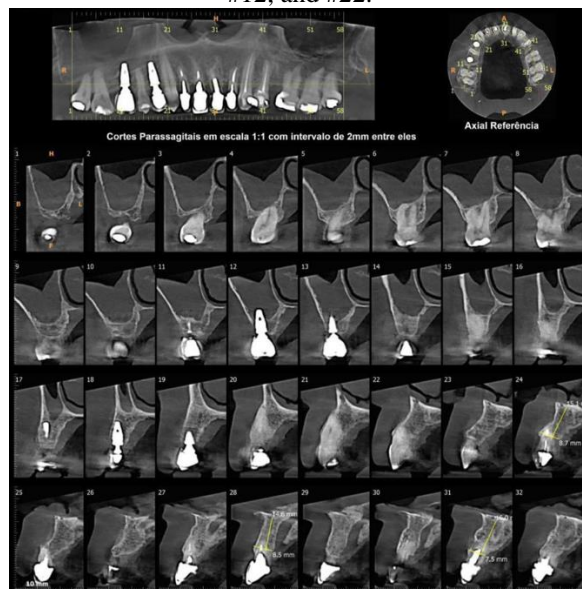
Source: author's personal archives

Figure 2: Initial panoramic X-ray.



Source: author's personal archives

Figure 3: Initial cone beam computed tomography (CBCT) scan, demonstrating bone loss around teeth #11, #21, #12, and #22.



Source: author's personal archives

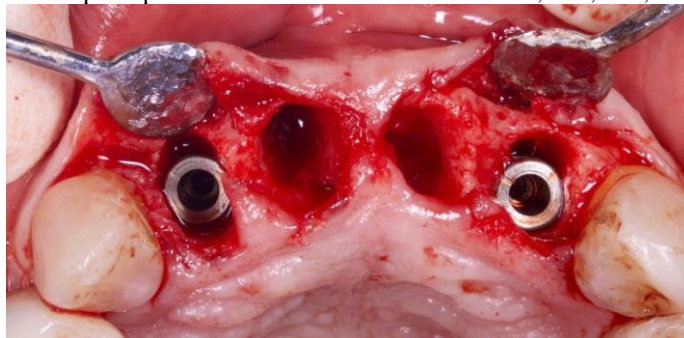
## TREATMENT PLANNING AND EXECUTION

Treatment began with periodontal probing of the four anterior incisors to determine pocket depth, as well as mobility testing to assess severity. After technical evaluation, all four incisors were deemed hopeless, and surgical and prosthetic planning was established.

The four anterior incisors were removed after preliminary impressions were taken for fabrication of a provisional prosthesis and a surgical guide to establish the natural position of the original teeth. Following extractions, implants were placed, the biomaterial was applied, and provisional crowns were fabricated over the installed implants.

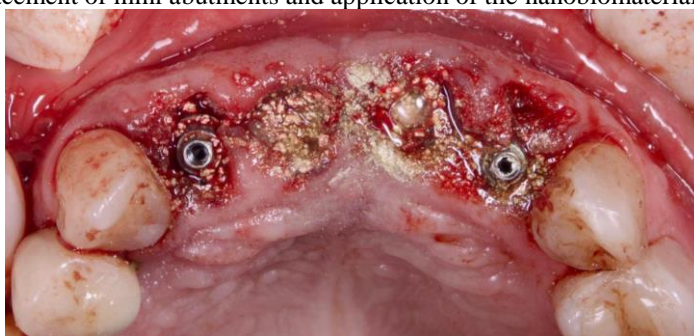Approximately six months after the initial treatment, the second phase was planned, consisting of installation of definitive ceramic crowns. The clinical case was conducted in accordance with bioethical guidelines governing the SLM (DF, Brasília, Brazil), with prior signed patient consent.

Figure 4: Implant placement after removal of teeth #11, #21, #12, and #22.



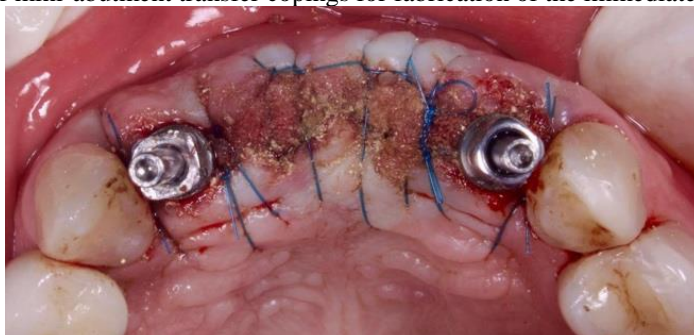Source: author's personal archives

Figure 5: Placement of mini abutments and application of the nanobiomaterial Blue Bone®.



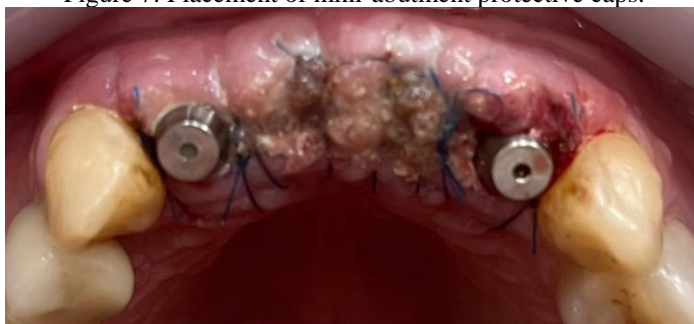Source: author's personal archives

Figure 6: Placement of mini-abutment transfer copings for fabrication of the immediate provisional prosthesis.



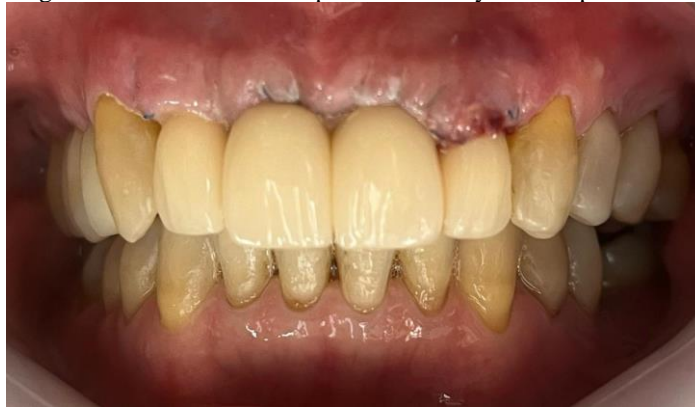Source: author's personal archives

Figure 7: Placement of mini-abutment protective caps.



Source: author's personal archives

Figure 8: Installation of the provisional acrylic resin prosthesis.



Source: author's personal archives

## BIOMATERIALS AND DENTAL IMPLANTS

For bone reconstruction surgery, the alloplastic nanobiomaterial Blue Bone® (Regener®, Curitiba, Brazil) was used. The implants were Avantt cone Morse implants, measuring  $3.5 \times 13$  mm (Systhex®, Curitiba, Brazil).

### Surgical Procedures

All surgical procedures, including follow-up evaluations, were performed at the Clínica de Hálito in Pernambuco (PE), Brazil.

Amoxicillin (Amoxil®, GlaxoSmithKline, Brentford, UK) 2 g orally was administered 1 hour prior to surgery, along with 0.12% chlorhexidine gluconate (Periogard®, Colgate, New York, USA). Mouth rinsing was performed immediately before surgery.

Local anesthesia was achieved using 2% lidocaine hydrochloride with epinephrine 1:100,000 (Alphacaine 100®, DFL, Rio de Janeiro, Brazil). Tooth extractions were performed as atraumatically as possible to preserve soft and hard tissues. The surgical guide was then positioned, and cone Morse implants ( $3.5 \times 13$  mm; Systhex®, Curitiba, Brazil) were placed in the regions of teeth #12 and #22.

Subsequently, the guide was removed, and prosthetic abutments were installed and cemented, with dimensions of  $3.3 \times 6.0 \times 2.5$  mm. Guided bone regeneration was then initiated on the buccal aspect of teeth #11, #21, #12, and #22. The gaps between the implants and the remaining buccal bone plate were immediately filled with the nanobiomaterial composed of Nano-HA/ $\beta$ -TCP (Blue Bone®, Regener®, Brazil), and provisional restorations were installed.

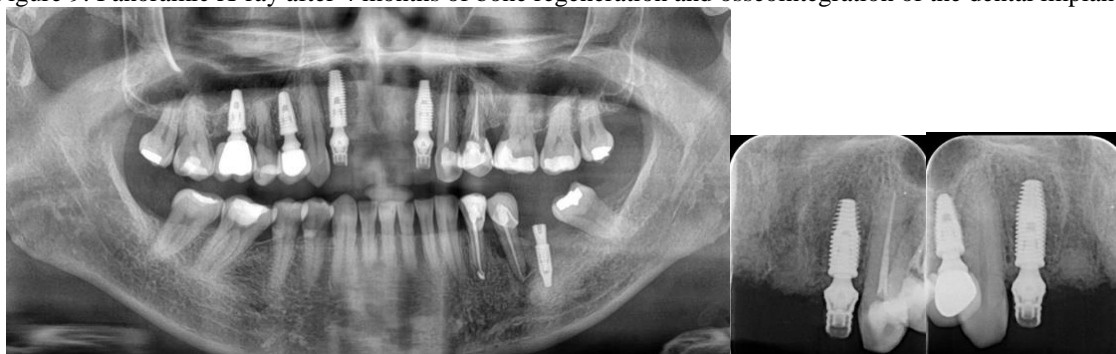## Results and Follow-Up

After a 6-month osseointegration period, complete adaptation of the tissues involved in the regenerative process was observed, with excellent stability and satisfactory esthetics. After clinical testing of implant stability, four splinted definitive crowns were fabricated using manually layered ceramic (Noritake EX-3 porcelain, Tokyo, Japan).

Occlusion was evaluated using articulating paper during lateral movements and contact points, achieving adequate cervical margin adaptation and ideal esthetic conditions. The results were highly satisfactory and approved by the patient.

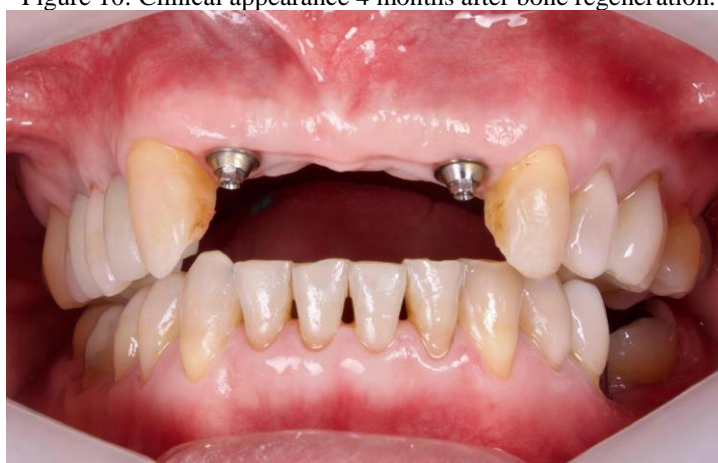The patient was followed monthly for 14 months, during which implant stability, possible bone loss, gingival health, and occlusal changes were assessed (Figures 9 -13).

Figure 9: Panoramic X-ray after 4 months of bone regeneration and osseointegration of the dental implants.



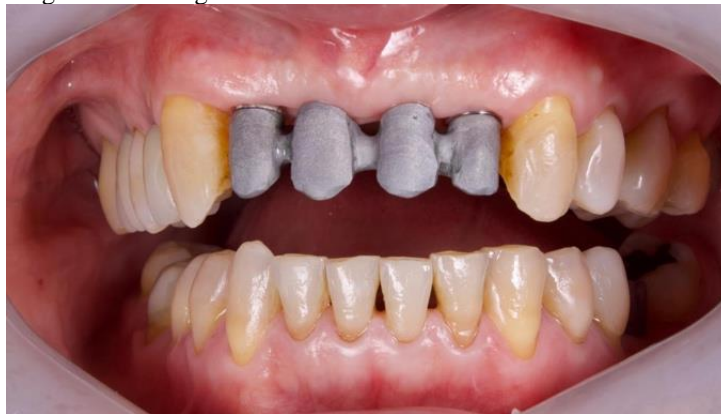Source: author's personal archives

Figure 10: Clinical appearance 4 months after bone regeneration.



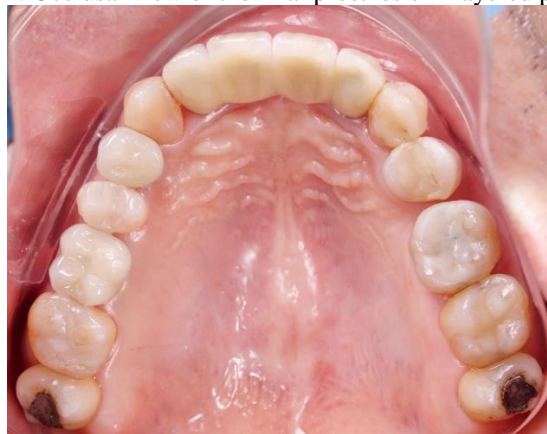Source: author's personal archives

Figure 11: Fitting of the metal framework on the mini abutments.



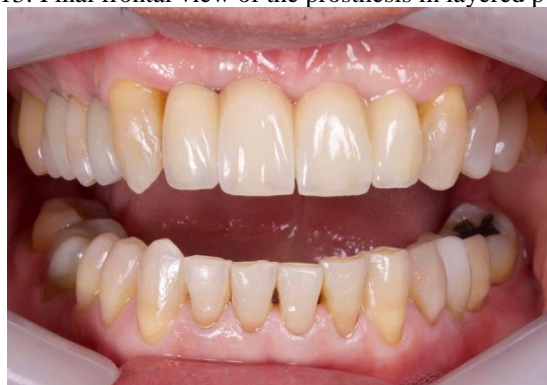Source: author's personal archives

Figure 12: Occlusal view of the final prosthesis in layered porcelain.



Source: author's personal archives

Figure 13: Final frontal view of the prosthesis in layered porcelain.



Source: author's personal archives

## DISCUSSION

A study evaluating 12 patients with more than 100 implants, including 65 placed immediately after extraction, reported a success rate of 98.2% after 6 months of follow-up (El

assal *et al.*, 2018). In the present case, although it involved only one patient, periodontal and bone tissue health was monitored for 14 months, demonstrating short- and medium-term treatment success.

A systematic review evaluating 288 patients treated with implants in the anterior maxilla, with follow-up ranging from 3 to 60 months, reported a success rate of 90.5%. This finding confirms that immediate loading is a safe and effective approach that does not negatively affect success rates, which is particularly important considering that cases involving immediate provisionalization tend to achieve higher esthetic satisfaction (Lerner *et al.*, 2020). Similar outcomes were observed in the present case, with complete alveolar regeneration and maintenance of volume and height following tooth extraction and placement of nanobiomaterial.

A controlled trial using PubMed data stated that immediate implant placement and immediate loading can be considered predictable and safe treatment options for single anterior maxillary restorations, with adequate survival rates and favorable esthetic outcomes for up to 5 years (Ogawa *et al.*, 2022). Such scientific evidence is highly relevant to support cases like the one presented, as it establishes success standards for the applied technique.

The use of nanobiomaterials in the anterior region has been widely adopted to improve esthetic outcomes by promoting greater stability and predictability, (Wittneben *et al.*, 2023; Brum *et al.*, 2024; Kamal *et al.*, 2019; Brum *et al.*, 2021). While some authors report satisfactory results using autogenous bone harvested from the tuberosity region, the present case demonstrated significant functional and esthetic outcomes using only a synthetic nanometric biomaterial, [He *et al.*, 2022; Salviano *et al* 2021; Brum *et al* 2020; Kubasiewicz-ross *et al* 2017).

## CONCLUSION

It can be concluded that the use of nanobiomaterials, associated with proper grafting techniques and precise three-dimensional positioning of dental implants, can achieve long-lasting esthetic and functional outcomes, thereby providing greater patient well-being.

## REFERENCES

BRUM, I. D. S.; FRIGO, L.; RIBEIRO DA SILVA, J. F.; CIAMBARELLA, B. T.; NASCIMENTO, A. L. R.; PEREIRA, M. J. D. S.; ELIAS, C. N.; DE CARVALHO, J. J. Comparison between nano-hydroxyapatite/beta-tricalcium phosphate composite and autogenous bone graft in bone regeneration applications: biochemical mechanisms and morphological

analysis. **International Journal of Molecular Sciences**, v. 26, n. 1, p. 52, 2024. DOI: 10.3390/ijms26010052.

BRUM, I. DA S.; FRIGO, L.; DEVITA, R. L.; PIRES, J. L. DA S.; OLIVEIRA, V. H. V. DE; NASCIMENTO, A. L. R.; DE CARVALHO, J. J. Histomorphometric, immunohistochemical, ultrastructural characterization of a nano-hydroxyapatite/beta-tricalcium phosphate composite and a bone xenograft in sub-critical size bone defect in rat calvaria. **Materials**, v. 13, n. 20, p. 4598, 2020. DOI: 10.3390/ma13204598.

BRUM, I. DA S.; FRIGO, L.; DOS SANTOS, G. P.; ELIAS, C. N.; DA FONSECA, G. A. M. D.; DE CARVALHO, J. J. Performance of nano-hydroxyapatite/beta-tricalcium phosphate and xenogenic hydroxyapatite on bone regeneration in rat calvarial defects: histomorphometric, immunohistochemical and ultrastructural analysis. **International Journal of Nanomedicine**, v. 16, p. 3473–3485, 2021. DOI: 10.2147/IJN.S301470.

BUZATU, B. L. R.; BUZATU, R.; LUCA, M. M. Impact of Vitamin D on osseointegration in dental implants: a systematic review of human studies. **Nutrients**, v. 16, n. 2, p. 209, 2024. DOI: 10.3390/nu16020209.

DHALIWAL, J. S.; ABD RAHMAN, N. A.; MING, L. C.; DHALIWAL, S. K. S.; KNIGHTS, J.; ALBUQUERQUE JUNIOR, R. F. Microbial biofilm decontamination on dental implant surfaces: a mini review. **Frontiers in Cellular and Infection Microbiology**, v. 11, p. 736186, 2021. DOI: 10.3389/fcimb.2021.736186.

EL ASSAL, D. W.; SAAFAN, A. M.; MOUSTAFA, D. H.; AL-SAYED, M. A. The effect of combining laser and nanohydroxy-apatite on the surface properties of enamel with initial defects. **Journal of Clinical and Experimental Dentistry**, v. 10, n. 5, p. e425–e430, 2018. DOI: 10.4317/jced.54371.

HE, Y.; PENG, Y.; LIU, L.; HOU, S.; MU, J.; LAN, L.; CHENG, L.; SHI, Z. The relationship between osteoinduction and vascularization: comparing the ectopic bone formation of five different calcium phosphate biomaterials. **Materials**, v. 15, n. 10, p. 3440, 2022. DOI: 10.3390/ma15103440.

HEIMES, D.; BECKER, P.; PABST, A.; SMEETS, R.; KRAUS, A.; HARTMANN, A.; SAGHEB, K.; KÄMMERER, P. W. How does dental implant macrogeometry affect primary implant stability? A narrative review. **International Journal of Implant Dentistry**, v. 9, n. 1, p. 20, 2023. DOI: 10.1186/s40729-023-00485-z.

JADHAV, L.; MADIWAL, V.; RAJWADE, J. M. The dental implant surface: a review of the past, present and future. **Journal of Materials Science: Materials in Medicine**, v. 37, n. 1, p. 21, 2026. DOI: 10.1007/s10856-025-06997-x.

KAMAL, M.; ANDERSSON, L.; AL-ASFOUR, A.; BARTELLA, A. K.; GREMSE, F.; ROSENHAIN, S.; GABATO, S.; HÖLZLE, F.; KESSLER, P.; LETHAUS, B. Bone regeneration in rabbit calvarial critical-sized defects filled with composite in situ formed xenogenic dentin and biphasic tricalcium phosphate/hydroxyapatite mixture. **Journal of Biomedical Materials Research Part B: Applied Biomaterials**, v. 107, n. 3, p. 773–782, 2019. DOI: 10.1002/jbm.b.34171.

KUBASIEWICZ-ROSS, P.; HADZIK, J.; SEELIGER, J.; KOZAK, K.; JURCZYSZYN, K.; GERBER, H.; DOMINIAK, M.; KUNERT-KEIL, C. New nano-hydroxyapatite in bone defect regeneration: a histological study in rats. **Annals of Anatomy**, v. 213, p. 83–90, 2017. DOI: 10.1016/j.aanat.2017.05.010.

LERNER, H.; HAUSCHILD, U.; SADER, R.; GHANAATI, S. Full-arch fixed reconstruction using guided surgery and immediate loading: a retrospective clinical study in 12 patients with 1-year follow-up. **BMC Oral Health**, v. 20, n. 1, p. 15, 2020. DOI: 10.1186/s12903-019-0941-z.

OGAWA, T.; SITALAKSMI, R. M.; MIYASHITA, M.; MAEKAWA, K.; RYU, M.; KIMURA-ONO, A. et al. Effectiveness of the socket shield technique in dental implants: a systematic review. **Journal of Prosthodontic Research**, v. 66, n. 1, p. 12–18, 2022. DOI: 10.2186/jpr.D\_20\_00054.

OU, P.; ZHANG, T.; WANG, J.; LI, C.; SHAO, C.; RUAN, J. Microstructure, mechanical properties and osseointegration ability of Ta-20Zr alloy used as dental implant material. **Biomedical Materials**, v. 17, n. 4, 2022. DOI: 10.1088/1748-605X/ac6b05.

ROMA, M.; HEGDE, S. Implications of graphene-based materials in dentistry: present and future. **Frontiers in Chemistry**, v. 11, p. 1308948, 2024. DOI: 10.3389/fchem.2023.1308948.

SALVIANO, S. H.; AMORIM LOPES, J. C.; BRUM, I. D. S.; FRIGO, L.; DOS SANTOS, M. J.; CONSONNI, S. R.; DE CARVALHO, J. J. Histomorphometric evaluation of bone-guided regeneration in maxillary sinus floor augmentation using nano-hydroxyapatite/beta-tricalcium phosphate composite biomaterial: a case report. **International Medical Case Reports Journal**, v. 14, p. 697–706, 2021. DOI: 10.2147/IMCRJ.S315757.

SHAH, A.; SINGH, K.; RAO, J.; TIWARI, B.; SINGH, K. D. Significance of 25(OH) D3 in early dental implant failure (EDIF) during osseointegration: a systematic review. **National Journal of Maxillofacial Surgery**, v. 14, n. 3, p. 360–368, 2023. DOI: 10.4103/njms.njms\_192\_22.

SHAHEEN, S. D.; ABOELWAF, M. R. The impact of fluorinated graphene versus nanohydroxyapatite crystals on artificial white spot lesion microhardness and color change. **BMC Oral Health**, v. 25, n. 1, p. 1041, 2025. DOI: 10.1186/s12903-025-06410-7.

WITTNEBEN, J. G.; MOLINERO-MOURELLE, P.; HAMILTON, A.; ALNASSER, M.; OBERMAIER, B.; MORTON, D. et al. Clinical performance of immediately placed and immediately loaded single implants in the aesthetic zone: a systematic review and meta-analysis. **Clinical Oral Implants Research**, v. 34, suppl. 26, p. 266–303, 2023. DOI: 10.1111/clr.14172.